
HIV Facial Lipoatrophy: Causes and Treatment Options

DEREK JONES, MD

Division of Dermatology, David Geffen School of Medicine, University of California at Los Angeles, Los Angeles, California

BACKGROUND. Human immunodeficiency virus (HIV)-associated facial lipoatrophy is becoming epidemic and may seriously affect quality of life.

OBJECTIVE. To review the possible causes and treatment options for HIV facial lipoatrophy.

METHODS. This article is based on a review of the medical literature and the author's clinical experience in treating HIV facial lipoatrophy.

DEREK JONES, MD, HAS INDICATED NO SIGNIFICANT INTEREST WITH COMMERCIAL SUPPORTERS.

HUMAN IMMUNODEFICIENCY virus (HIV) facial lipoatrophy is becoming epidemic and may stigmatize affected individuals and severely impact quality of life. Usually, those affected have well-controlled HIV disease and are otherwise healthy, but their characteristic facial appearance may suggest quite the opposite. The psychological effects are often devastating. There are now over 42 million people living with HIV worldwide, with an estimated 1 million in the United States alone.¹ With 50% or more of HIV-infected individuals manifesting facial lipoatrophy,² the demand for effective, safe, and affordable treatments is rising.

HIV facial lipoatrophy is often considered a manifestation of HIV-associated lipodystrophy, a syndrome that may include low-density lipoprotein hypercholesterolemia, hypertriglyceridemia, impaired glucose tolerance, lactic acidosis, and generalized wasting of fat or lean tissue mass. Specific morphologic changes include regional fat accumulation (abdominal visceral, dorsocervical, and/or breast enlargement) and regional fat loss in the arms and legs, buttocks, and face. The heterogeneity of findings in HIV lipodystrophy may reflect more than one syndrome. This article focuses specifically on possible causes of HIV facial lipoatrophy and treatment options.

Causes and Mechanisms

In the mid-1990s, combination therapy for HIV, frequently called highly active antiretroviral therapy (HAART), changed HIV infection from a once certain death sentence into a chronic, manageable disease. When the lipodystrophy syndrome surfaced soon thereafter, the blame was placed squarely on protease inhibitor (PI) ther-

CONCLUSION. Although absorbable injectable fillers and implants are helpful in treating HIV facial lipoatrophy, they are limited by cost and the short duration of correction. Newer forms of longer-lasting fillers (poly-L-lactic acid [Sculptra]) and permanent injectable fillers (liquid injectable silicone) are proving useful for treatment of this condition.

apy, a frequent component of HAART. Studies suggest that PIs mediate lipoatrophy by targeting sterol regulatory element binding protein 1, which is involved in adipocyte differentiation.³

More recently, nucleoside reverse transcriptase inhibitor (NRTI) therapy, another frequent component of HAART, has been implicated as a cause of lipoatrophy.⁴ NRTIs deplete mitochondrial deoxyribonucleic acid (DNA) by inhibiting mitochondrial DNA polymerase, which may result in fat cell apoptosis. It has been suggested that thymidine analogue NRTIs (stavudine, zidovudine) are more toxic to mitochondrial DNA than the newer non-thymidine analogue NRTIs, such as abacavir,⁵ although all drugs in this class may deplete mitochondrial DNA.

Lipoatrophy can occur in the absence of NRTI and/or PI therapy, with epidemiologic studies suggesting that drugs alone are not the sole cause.² In the HIV Outpatient Study (HOPS), 1,077 patients were evaluated for fat maldistribution. Lipoatrophy was associated with the use of indinavir (a PI) for longer than 2 years and with any use of stavudine (an NRTI). However, independent, nondrug risk factors also strongly associated with lipoatrophy included increasing age (> 40 years), white race, CD4 count < 100 cells/mm³ or < 100 cells/mm³ at the nadir, body mass index loss, and longer duration and severity of HIV disease. The number of nondrug risk factors substantially increased the likelihood of lipoatrophy. If nondrug risk factors were absent, lipoatrophy was unusual regardless of the duration of drug use. The results suggest that the cause of lipoatrophy is multifactorial and may be the result of long-standing HIV infection. Expression of tumor necrosis factor α from subcutaneous adipocytes in vitro is higher among those with HIV lipoatrophy,³ and it has been suggested that persistent activation of inflammatory cytokines in HIV infection may mediate lipoatrophy.

Address correspondence and reprint requests to: Derek Jones, MD, 9201 Sunset Blvd, #602, Los Angeles, CA 90069.

In conclusion, HIV lipoatrophy is still incompletely understood and may be caused by drug therapy, genetic predisposition, immune reconstitution, cytokine activation, HIV infection itself, hormonal influences, or other as yet unidentified influences. Whatever the etiology, the fat loss is apparently irreversible. The psychological effects are often devastating, with patients experiencing poor body image, low self-esteem, depression, social isolation, and career barriers.⁶ Those affected are often desperate for treatment options, particularly treatment options that offer affordable, persistent, and long-term correction.

Treatment Options

Systemic Therapy

In so-called "switch studies," switching from a thymidine analogue NRTI (stavudine, zidovudine) to a non-thymidine analogue NRTI (abacavir) resulted in a modest increase in peripheral limb fat at 24 weeks as measured by computed tomography (CT) and dual-energy x-ray absorptiometry, although the effect was not clinically apparent.⁵ Switching therapy in response to lipoatrophy may incur risk, such as viral rebound and adverse drug events. Furthermore, prolonged treatment interruption (> 6 months) does not yield clinically evident improvement in lipoatrophy. Some physicians are now recommending regimens that spare drugs more likely to be associated with lipoatrophy. However, in choosing treatment regimens, the physician must also account for viral drug sensitivities and HIV severity in addition to the potential risks of drug therapy.

The thiazolidinediones (rosiglitazone, pioglitazone) are antidiabetic agents that improve insulin resistance in type 2 diabetes mellitus. They may cause fat gain in some patients and may increase fat mass in familial forms of lipoatrophy.⁷ A prospective study comparing rosiglitazone 8 mg daily with placebo in 15 HIV lipodystrophy patients showed no change in fat mass at 24 weeks, as measured by magnetic resonance imaging.⁸ However, in another study, some patients receiving rosiglitazone 8 mg daily ($n = 8$) achieved a $23 \pm 10\%$ increase in subcutaneous adipose tissues after 6 to 12 weeks of therapy as measured by CT.⁹ Larger-scale studies are needed.

Anabolic steroids may actually decrease subcutaneous fat and aggravate HIV lipoatrophy, although they are useful in combating body mass index loss.¹⁰ Human growth hormone is not a useful treatment for HIV facial lipoatrophy, although it may be useful for HIV lipoaccumulation, particularly in the abdominal visceral region.¹¹

Soft Tissue Augmentation: Temporary Options

Zyplast Collagen

Jones recently analyzed 100 patients who underwent correction of HIV facial lipoatrophy over a 3-year period (Figure 1).¹² Zyplast collagen was injected into the sub-

dermal plane in aliquots of 0.1 cc to prevent lumpiness. Only cheek areas were treated. The average volume of collagen per treatment was 4 cc. Average time to patient-initiated follow-up for reinjection was 136 days (4.5 months), with 66% of patients returning for at least one reinjection. Before and after photographs were rated by investigators not involved in treatment. On average, 4 cc of collagen resulted in a one-stage improvement on the Carruthers' lipoatrophy scale (0 = no lipoatrophy; 4 = severe lipoatrophy).¹³ Anecdotally, clinical persistence of correction in most patients without retreatment was, at most, 20 to 30% at 6 months. Adverse reactions occurred in 0.01% of treatments and were limited to temporary palpable lumpiness in five patients and collagen necrosis leading to mild scar formation in one patient. It is suggested that lumpiness and necrosis can be avoided by injecting strictly into the subdermal plane, aspirating before injecting, limiting volume to 0.1 cc per needle insertion, and placing injections 2 to 3 mm apart. The reasons for discontinuation of treatments included short duration of correction, unnatural feel of collagen beneath the skin, and excessive cost related to the necessity of large volumes and repeat injections.

Micronized Alloderm (Cymetra)

Tsao evaluated 25 patients with HIV facial lipoatrophy treated with injectable micronized Alloderm.¹⁴ Alloderm was reconstituted with 3 cc of 1% lidocaine with 1:100,000 epinephrine to achieve a concentration of 330 mg/cc. Six to 12 cc of Alloderm was injected into the mid- to deep dermis of affected facial sites (medial cheeks and temples). Patients were evaluated at 1 and 3 months postinjection and retreated as needed. All patients experienced complete augmentation of their facial lipoatrophy. The results started to fade at 1 month, and most patients had returned to their pretreatment lipoatrophy baseline within 3 months. Side effects were minimal and included expected postinjection erythema and edema lasting 24 to 48 hours. No infections, scarring, allergic reactions, or other adverse complications were seen. Injectable Alloderm was considered a safe and effective treatment option. However, as with Zyplast collagen, excessive cost and the necessity of frequent treatments with large volumes limit the utility of micronized Alloderm for this indication.

Fascian

Fascian is preserved human particulate fascia lata for injection. It has been proposed that injection with Fascian will typically generate new native collagen deposition in the treatment area.¹⁵ This has stimulated some physicians to try Fascian for correction of HIV facial lipoatrophy, although formal studies are lacking. Physicians with significant experience with Fascian for HIV facial lipoatrophy state that the results are disappointing. Brody informally analyzed 30 of his HIV facial lipoatrophy patients treated with Fascian.¹⁶ The substance reabsorbed very

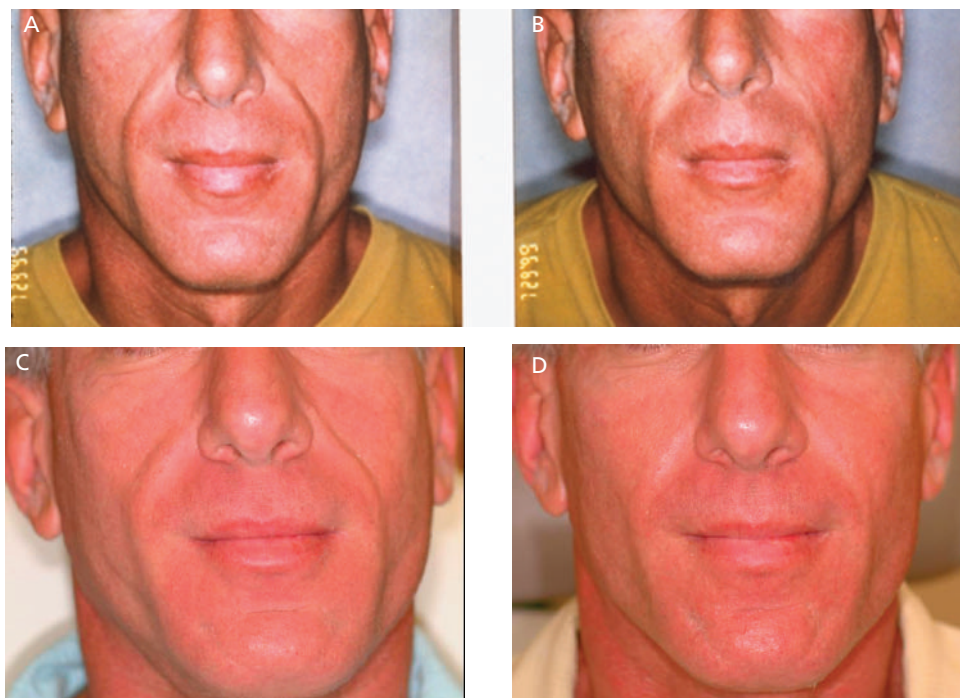


Figure 1. (A) Before collagen. (B) Immediately after 3 cc collagen. (C) One year after collagen. (D) After 6.45 cc microdroplet silicone over five monthly visits (the photograph was taken 3 months after the last silicone injection).

quickly with less than 25% correction, remaining, on average, at 2 months post-treatment with 240 to 320 mg of 1.0 mm particle size. With maintenance treatments performed every 6 to 8 weeks with 160 to 240 mg of the 1.0 mm particle size, most had persistence of less than 25 to 50% every time they returned at the 6- to 8-week interval. Brody commented that “the results with Fascian, therefore, are not as sustaining as with Zyplast and are therefore disappointing.”

Fat Transfer

As HIV lipoatrophy represents the loss of the patient's own subcutaneous fat, it seems logical that autologous fat transfer would be the most appropriate treatment option (Figure 2). A recent study reported on 29 patients with HIV facial lipoatrophy who underwent autologous fat transplant with the Coleman method.¹⁷ The technique was deemed reliable, and photographs at 6 months showed the durability of the fat graft. However, the authors noted that the majority of patients with HIV facial lipoatrophy lack adequate subcutaneous donor fat reserves, so many are not candidates for the procedure. Jones performed fat transfer on 10 HIV facial lipoatrophy patients with similar methods and results.¹⁶ However, in almost all cases, the correction did not persist for longer than 12 months. Another recent study also suggested that although autologous fat transfer is effective for this condition, HIV lipoatrophy patients frequently have minimal donor fat reserves and that touch-up treatments requiring reharvesting of fat

are usually necessary over time.^{18,19} HIV patients often lose fat subcutaneously in the abdomen and buttocks, which are the usual fat transfer donor sites. It is logical that fat cells donated from these areas may continue to dwindle as lipoatrophy progresses. An interesting potential donor site is fat obtained from liposuction of HIV-related dorsocervical fat accumulation. Fat from this area is probably metabolically much different from subcutaneous fat in the abdomen and buttock area, and anecdotal reports suggest that fat transferred from this area seems to persist.¹⁶

Poly-L-Lactic Acid (NewFill)

Poly-L-lactic acid (NewFill, Medifill, London, UK; Biotech Industrie SA, Luxembourg) (Sculptra, Dermik Laboratories, Berwyn, PA, USA) is an injectable bioabsorbable material. Injectable poly-L-lactic acid (Sculptra) received approval from the US Food and Drug Administration (FDA) on August 3, 2004, and is specifically indicated for treatment of HIV facial lipoatrophy (Figure 3). Poly-L-lactic acid is purported to be immunologically inert and has been widely used as a vehicle for subcutaneously or intramuscularly injected drugs or as a dissolvable bone implant or absorbable suture. Gradual reabsorption is typically expected over a 2- to 3-year period.²⁰ A study in 2000 analyzed 26 male patients who received poly-L-lactic acid for HIV-related facial wasting.²¹ Patients received four injections, each performed every 2 weeks (3 cc in each cheek). Ultrasonography of the cheeks was performed by the same radiologist on day -14 and at weeks 12 and 24, allowing

for measurements of dermal and fat thickness. The mean baseline dermal thickness was 2.7 mm. The mean dermal thickness rose by 4.1 mm (151% increase) and 5.31 mm (196% increase) at weeks 12 and 24, respectively ($p = .0001$). Twenty-two of 26 patients felt that their post-treatment facial appearance had returned to a shape similar to that prior to the onset of facial wasting.

Another recent European study evaluated 30 patients with HIV-associated facial lipoatrophy who were treated with NewFill.²⁰ Patients were randomized into immediate and delayed treatment arms. The immediate group received three bilateral injections 2 weeks apart into the deep dermis overlying the buccal fat pad at weeks 0, 2, and 4, whereas the delayed group received the same treatment at weeks 12, 14, and 16. Four to 5 mL of fluid was injected at each session. Adverse events were uncommon and were limited to transient bruising in one patient and localized

cellulitis in another. Assessments included facial ultrasonography, visual analogue scales, the Hospital and Anxiety Depression Scale, and ratings from photographs at weeks 0, 12, and 24. At week 12, patients in the immediate treatment group had significantly better visual analogue scores and lower anxiety scores than the untreated patients in the delayed arm. Benefits persisted through week 24. Data beyond 24 weeks were not reported. It was noted that many patients did not achieve complete resolution of their facial lipoatrophy, and it was suggested that more treatments with larger total injection volumes may be useful for some patients with more severe lipoatrophy.

Another recent European study evaluated 44 HIV facial lipoatrophy patients treated with poly-L-lactic acid.²² Patients were injected with an average of 2.7 mL per injection session into each cheek. Injections were performed every 15 days until adequate correction was achieved. The

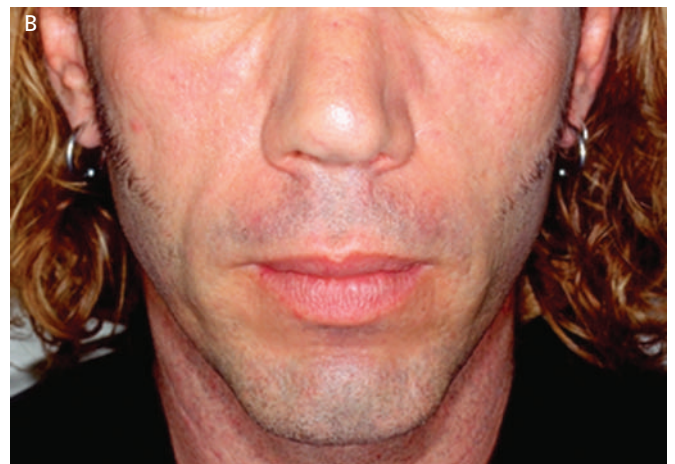
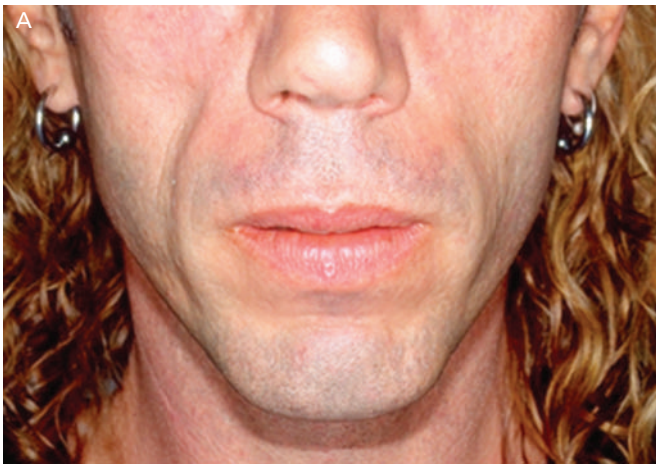
Figure 2. (A) Before autologous fat transfer. (B) Six months after fat transfer. This correction faded over the next 6 months.

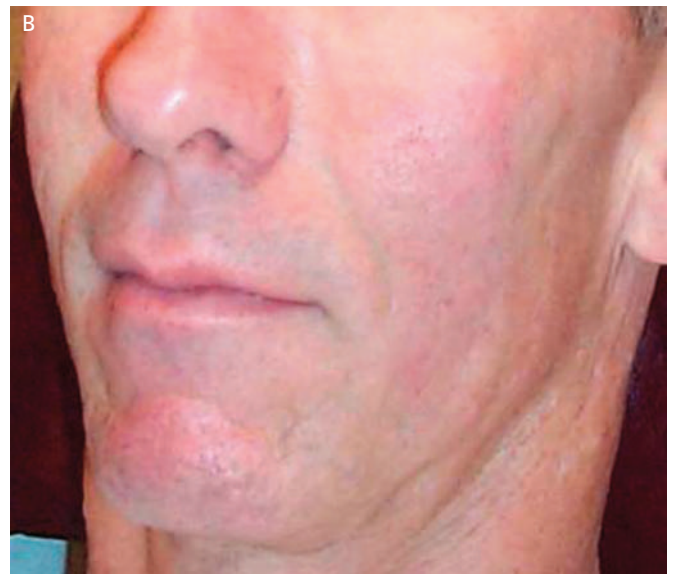
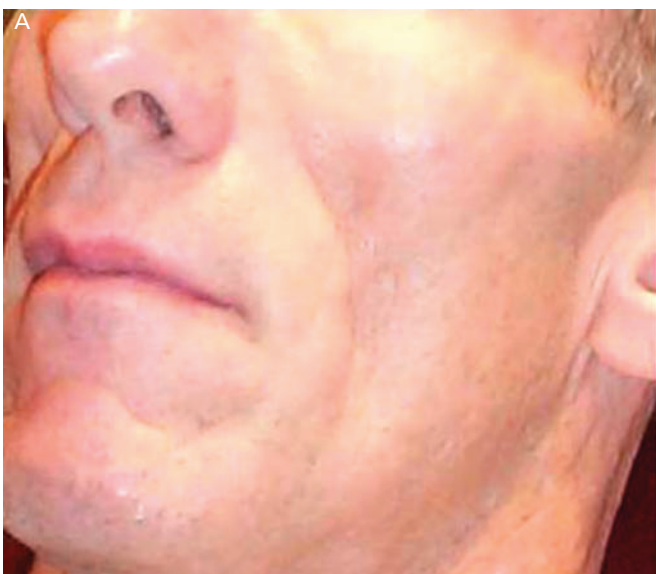
Figure 3. (A) Before NewFill (poly-L-lactic acid). (B) After Newfill (administered in several treatments over 6 months). Courtesy of Peter Englehard, DO.

mean number of injections was 4.4 (average total volume = 23.76 mL). Three-dimensional photographs were analyzed using digital surface topography software, which is capable of using photographs to measure the mean increase in skin thickness. Six months after the last injection, the mean increase in skin thickness was 3.4 mm for the right cheek and 2.2 mm for the left cheek. Patient self-satisfaction scores (0 = total dissatisfaction with facial appearance; 10 = total satisfaction with facial appearance) increased from 3.3 at baseline to 7.6 6 months after the last treatment. There was no change between pre- and post-treatment quality of life questionnaire scores. Adverse events included mild to moderate pain with injection in the majority of patients, post-treatment malaise in four patients, limited injection site bleeding in three patients, and ecchymosis in one patient.

The European VEGA study has followed patients treated with poly-L-lactic acid for 96 weeks.²³ Fifty patients with severe facial lipoatrophy received four sets of injections at day 0 and then every 2 weeks for 6 weeks. Patients were evaluated by clinical examination, facial ultrasonography, and photography at screening and at weeks 6, 24, 48, 72, and 96. At entry, the median facial fat thickness was 0 (range 0.0–2.1 mm). The median total cutaneous thickness increased significantly from baseline: +5.1 mm at week 6, +6.4 mm at week 24, +7.2 mm at week 48, +7.2 mm at week 72, and +6.8 mm at week 96 ($p < .001$). No adverse events were observed. In 22 (44%) patients, palpable but nonvisible subcutaneous nodules were observed, with a spontaneous resolution in six patients by week 96.

In my experience, patients achieving correction with poly-L-lactic acid generally state that the correction may dissipate after 6 to 12 months. In two patients treated with NewFill, I have observed visible, small, firm, superficial red

papules at the injection sites that persist over time (Figure 4). Biopsy revealed a granulomatous foreign body reaction in the dermis. Therefore, injectable poly-L-lactic acid cannot be considered completely biologically inert (ie, it is capable of triggering inflammatory reactions). It should be injected strictly into the subdermal plane because more superficial injection may cause visible granulomatous papules. As with collagen, fat, and hyaluronic acid, the use of NewFill may be limited by high cost and the necessity over time of repeat treatments with large volumes.

Hyaluronic Acid (Restylane, Perlane, Hylaform)

Hyaluronic acid is a polysaccharide component of soft tissue and is identical in all species and tissue types. Restylane (Medicis Aesthetics, Scottsdale, AZ, USA) and Hylaform (Inamed Aesthetics, Santa Barbara, CA, USA) have been FDA approved. Perlane is a non-animal-derived hyaluronic acid similar to Restylane but is composed of larger gel particle sizes, which may confer greater longevity of correction (Figure 5).

Studies suggest that hyaluronic acid may have greater longevity than collagen and may be a superior substance for filling deeper cutaneous defects.²⁴ Hyaluronic acid has been used successfully to treat HIV facial lipoatrophy.²⁵ However, as with other temporary fillers, large volumes are frequently necessary to achieve a complete correction, which tends to fade over 6 to 12 months (Chris Riess, MD, Zurich, Switzerland, personal communication, 2002). As with other temporary fillers, the high cost of large volumes and the need for repeated injections are limiting factors. Q-Med (Q-Med Esthetics, Uppsala, Sweden) is currently developing a larger gel particle size (Macrolane), which may confer greater longevity of correction (Kjell Rensfeldt, MD, personal communication, 2002).

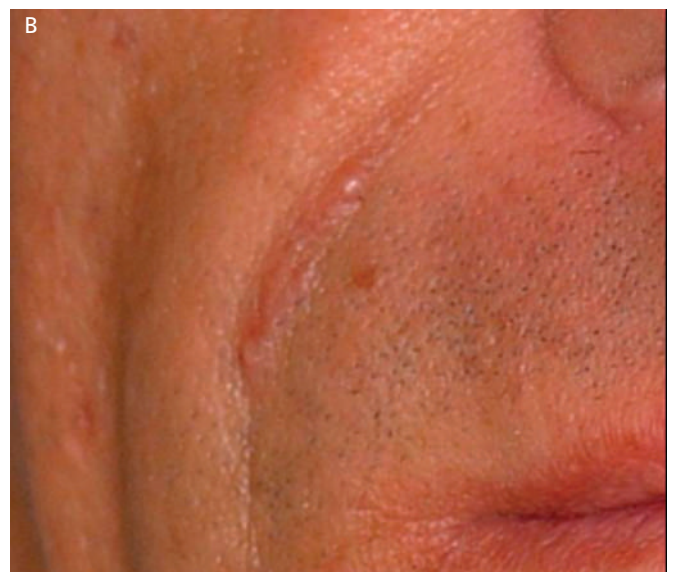
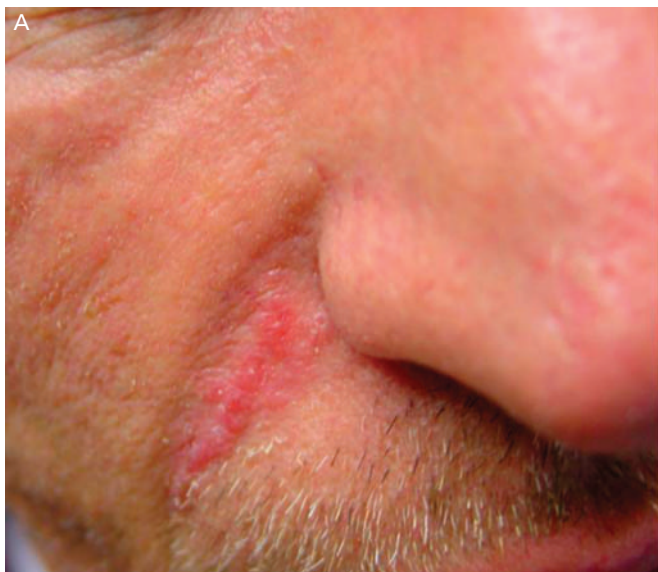
Figure 4. (A and B) Adverse reactions to NewFill with persistent firm erythematous nodules at injection sites.

Soft Tissue Augmentation: Permanent Options

Liquid Injectable Silicone

In the United States and Canada, FDA-approved forms of liquid injectable silicone are being used successfully off label to treat HIV facial lipoatrophy (Figure 6). Recently, Jones and colleagues reported their experience with highly purified 1,000-centistoke silicone oil for HIV facial lipoatrophy.²⁶ Currently, over 800 patients with HIV-associated facial lipoatrophy are being treated in an open pilot trial using a highly purified 1,000-centistoke silicone oil injected by microdroplet serial puncture technique. Data on 77 subjects with a complete correction were analyzed to determine the number of treatments, the amount of silicone, and the time required to reach complete correction relative to initial severity. The volume of silicone, number of treatments, and time required to reach a complete correction were directly related to the initial severity of the lipoatrophy ($p < .0001$). Supple, even facial contours were

routinely restored, with all patients tolerating treatments well. No adverse events were noted. Currently, liquid injectable silicone appears to be the most cost-effective treatment option in the United States. However, longer follow-up of treated patients is required to adequately assess the efficacy, durability, and longer-term safety of liquid injectable silicone for HIV facial lipoatrophy.

Expanded Polytetrafluoroethylene Implants

Glogau implanted SoftForm (expanded polytetrafluoroethylene [ePTFE], in tube design) in a series of patients to correct facial lipoatrophy.²⁷ Carruthers has also used ePTFE for this purpose (Alastair Carruthers, MD, personal communication, 2002). With ePTFE, permanent correction of HIV lipoatrophy is obtainable, but the correction is often incomplete. The implants fill the deep, triangular malar hollows but do not address the more subtle facial contour distortions that may be seen. Frequently post-treatment, the contour of the cheek is elevated but appears lumpy, with the implants feeling palpable and

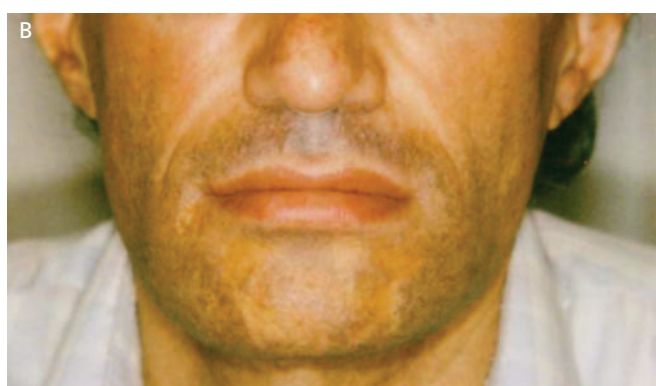
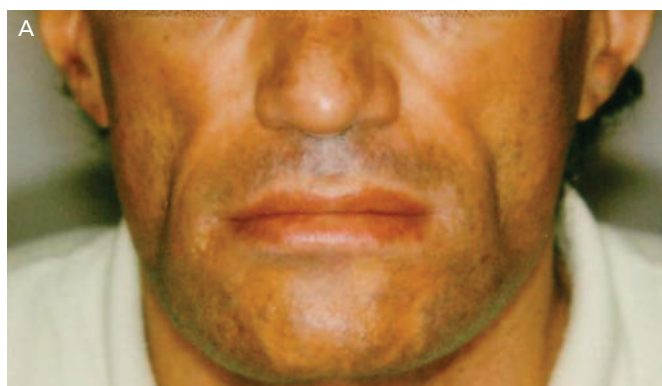
Figure 5. (A) Before Perlane. (B) After Perlane. Courtesy of Chris Riess, MD.

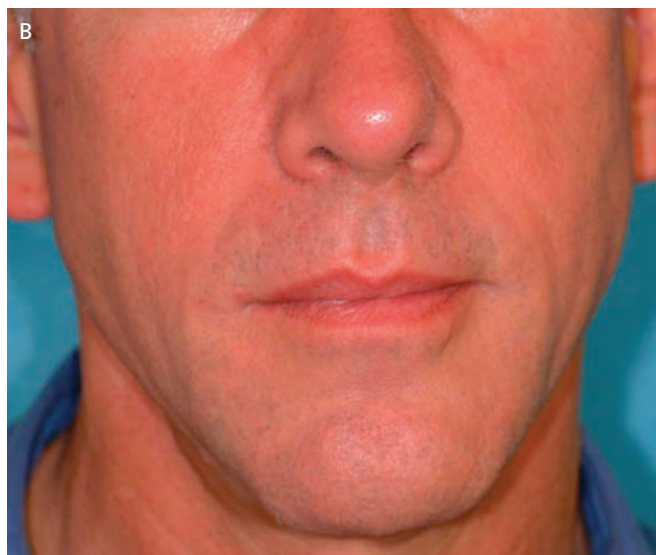
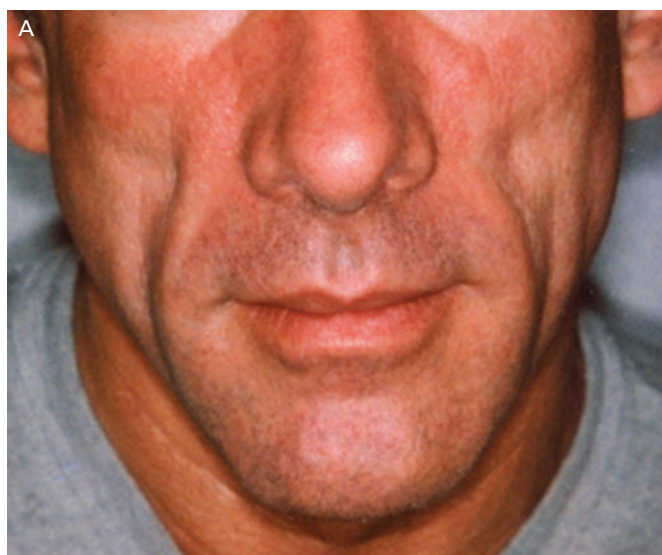


Figure 6. (A) Before microdroplet silicone. (B) After 12.5 cc of microdroplet silicone over eight monthly treatments (the photograph was taken 6 months after the last silicone injection).

firm to the touch (Figure 7). Carruthers and Jones successfully addressed this problem and smoothed the facial contour by performing microinjection silicone following ePTFE implantation, although both prefer microinjection silicone as first-line therapy (Alastair Carruthers, MD, personal communication, 2003). Implantation with ePTFE carries the risk of extrusion, movement, infection, and swelling.²⁸

Polymethylmethacrylate

Smooth microspheres of polymethylmethacrylate (PMMA) suspended in bovine collagen (Artecoll) or in a polysaccharide gel matrix may be injected for HIV facial lipotrophy. These substances are not FDA approved, although Artecoll is undergoing review for FDA approval. Serra, from Rio de Janeiro, Brazil, treated 184 patients with smooth PMMA microspheres suspended in a vehicle containing hydroxyethylcellulose and lidocaine (the

microspheres are reportedly from the same source as contained in Artecoll) (Figure 8).²⁹ The corrections were durable, safe, and esthetically excellent. Side effects were limited to temporary swelling, pain, and fever (two patients). Histopathology showed a diffuse granulomatous infiltrate in the subcutis, with extracellular vacuoles of different sizes but a uniformly round shape. Ultrasonography showed an increase in dermal thickness that was sustained even after 36 months. There was no change in CD4 count or viral load over time related to the procedure. Some patients needed new injections after 12 to 18 months in different areas from the previous injections or repeat injections in previously treated areas owing to lipotrophy progression. All patients were satisfied with the results and noted a great improvement in their quality of life. PMMA was demonstrated to be longer lasting when compared with collagen, poly-L-lactic acid, or fat implants. As the PMMA microspheres are suspended in an inexpensive

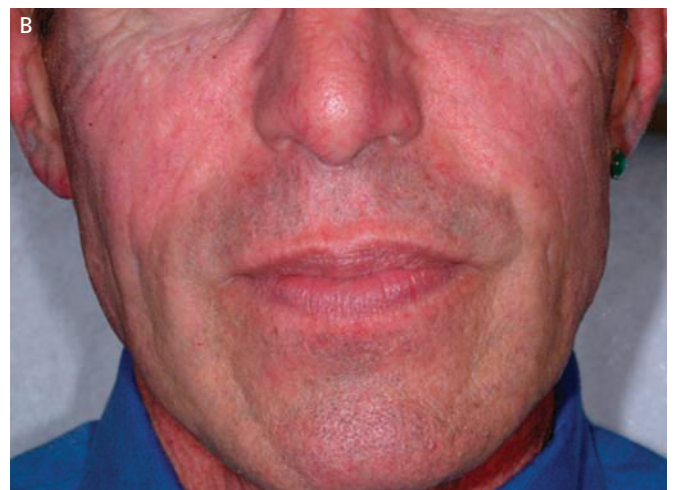
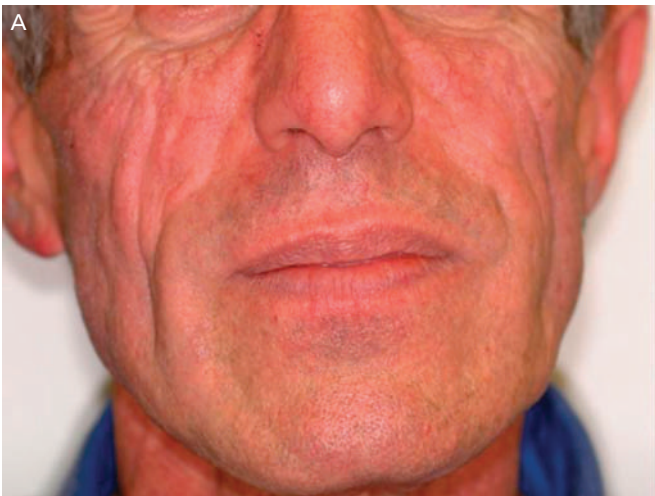


Figure 7. (A). After expanded polytetrafluoroethylene implants. Note palpable lumpiness. (B) After 11.4 cc microdroplet silicone over six monthly treatments (the photograph was taken 6 months after the last silicone injection).

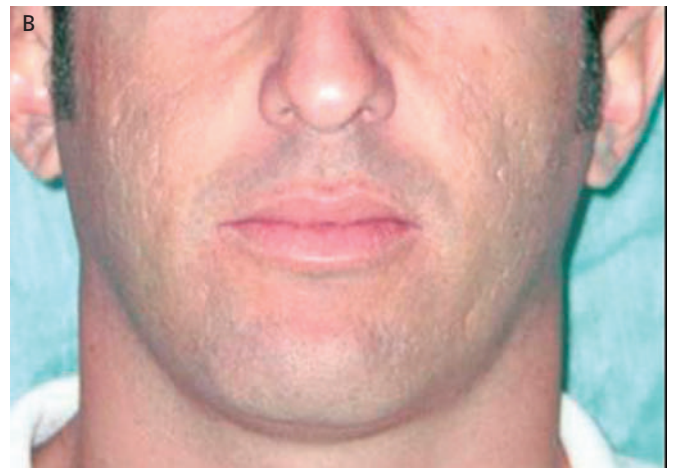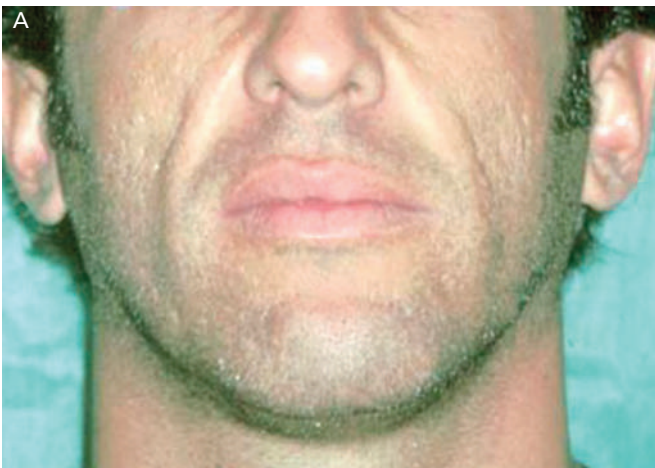


Figure 8. (A) Before polymethylmethacrylate. (B) Three months after injection of polymethylmethacrylate beads suspended in a hydroxyethylcellulose vehicle. Courtesy of Marcio Serra, MD.

polysaccharide gel matrix and not in bovine collagen, as with Artecoll, the treatments are significantly less expensive and more cost-effective over time.

The author (D. Jones) has noted palpable hardening of PMMA in the subcutis of two patients treated with this protocol. Recently, Serra began to inject microdroplet silicone after deeper depressions have been corrected with PMMA because silicone typically creates a smoother, more supple correction that feels more like natural subcutaneous tissue (Marcio Serra, MD, personal communication, 2003).

Polyacrylamide Gel and Other Synthetic Injectable Polymers

Del Pino has reported success injecting polyacrylamide gel (Aquamid, Contura, Denmark), a non-FDA-approved synthetic polymer, for the treatment of HIV facial lipoatrophy.³⁰ The product reportedly contains 97.5% water with 2.5% polyacrylamide. The gel is injected subcutaneously with larger volumes. Apparently, a fibrous capsule ultimately forms around the periphery of the balloon-like implants and imparts a long-lasting correction. Advocates of polyacrylamide-in-water products claim that the substance can be easily removed through a small incision and drainage procedure, although formal studies supporting this are lacking. On Contura's Web site, claims of the safety and efficacy of Aquamid are supported by descriptions of histologic studies and either retrospective or ongoing prospective human trials. None of the data, however, have been published in peer-reviewed medical journals. Recently, de Bree and colleagues reported a case of a severe granulomatous inflammatory response induced by injection of polyacrylamide gel into facial tissue.³¹ Another study analyzed the histologic and systemic effects of polyacrylamide gel injected subcutaneously in rats.³² The toxicity to the kidney was obvious. The local and histologic reaction was slight, and a thin, fibrous membrane formed around the implants, which gradually became stiff. The implants could not be withdrawn completely. The authors concluded that polyacrylamide gel has obvious cytotoxicity and is not a suitable material for soft tissue implantation. It should be noted that unpolymerized polymer is considered toxic to nerves and kidneys and that different polyacrylamide gels may contain varying amounts of unpolymerized acrylic monomers.

Precursor products to Aquamid include the non-FDA-approved Formacryl and Bioformacryl. These products have been anecdotally associated with cases of late-appearing infection, and impurities (unpolymerized acrylamide) may be toxic to nerves, kidneys, and other organs. A new and molecularly very similar product, polyalkylamide (Bio-Alcamid, Polymekon, Milan, Italy), is a nonreabsorbable acrylic acid-derived polymer with a reticulated structure characterized by alkylimide-amide groups. It is composed of 96% unpyrogenic water and 4% synthetic polymer. Like the polyacrylamide products, advocates of Bio-Alcamid

describe the product as biocompatible, nontoxic, nonallergenic, easily injectable, and quickly removable. A recent study suggests that Bio-Alcamid does not interfere with the morphologic and functional characteristics of human skin fibroblasts.³³ Another recent publication reported on the use of Bio-Alcamid in treating pectus excavatum, Poland's syndrome, postoperative trauma, and facial esthetic defects.³⁴ Twelve of 2,000 patients had postoperative *Staphylococcus* infections. Esthetic results were deemed excellent; tissues felt soft, and the implants were uniformly distributed. No migration or dislocation of the implants, no granulomas, and no allergic responses were identified. It should be noted that long-term studies of safety and efficacy are lacking. Although Bio-Alcamid is not FDA approved for any purpose, it has recently gained popularity among patients with HIV lipoatrophy, with large numbers of patients frequently traveling to Tijuana, Mexico, where they often receive injections from a nonphysician, unlicensed practitioner who promotes the product to this population. A recent publication discusses the European experience with Bio-Alcamid for HIV-associated lipoatrophy. The report is descriptive but does not present formal objective data or long-term follow-up.³⁵ Therefore, further well-designed, peer-reviewed studies are warranted.

Mixtures of different synthetic polymers, such as the Kuhra Vital injectable implants (Dermabiol Institute, Lucerne, Switzerland), are being produced outside the United States and, like Aquamid and Bio-Alcamid, are making their way into the HIV community for treatment of facial lipoatrophy. None are FDA approved for any use, and there are no well-designed, peer-reviewed studies supporting the safety and efficacy of these products. Implantation of any permanent nonbiodegradable synthetic material into the human body carries the risk of migration, toxicity, granuloma formation (lumps and nodules), pigment change, and infection, among others, all of which may appear many years after injection. Only careful toxicology testing and well-designed human trials, of the sort that the FDA would require, will ultimately prove the safety and efficacy of these products.

Radiesse (BioForm, San Mateo, CA, USA) consists of calcium hydroxylapatite microspheres suspended in an aqueous, polysaccharide gel. Apparently, it is long-lasting but ultimately bioabsorbable over months to years. It is FDA approved for treating vocal cord paralysis and for augmenting oral and maxillofacial defects. Some physicians in the United States are beginning to use it off-label for soft tissue augmentation, including HIV facial lipoatrophy. However, the substance is radiopaque, and anecdotal patient reports suggest that the product may harden over time. Formal studies evaluating the safety and efficacy of calcium hydroxylapatite for soft tissue augmentation are lacking. Sklar and White recently reviewed their experience with Radiesse.³⁶

Other Surgical Options

Many HIV patients have attempted surgical face-lifts to reduce the redundant facial skin created by their facial fat loss (Figure 9). In my experience, the facial depressions may initially improve with this method. However, the cheek hollows often return within several months, and patients frequently seek soft tissue augmentation. To quote an adage of the cosmetic dermatologist, "lifts lift and fillers fill." The basic defect in HIV facial lipoatrophy is one of volume loss. Therefore, generally, these patients need fillers, not lifting.

Other patients with HIV facial lipoatrophy have sought treatment with sheets of cadaveric dermal tissue (Alloderm) (Figure 10) or rigid, custom-designed Silastic implants placed through face-lift incisions (Figure 11).^{16,37} In my experience, Alloderm implants generally become reabsorbed over 12 to 24 months, and rigid alloplastic implants may feel firm, unforgiving, and unnatural.

Should lipoatrophy progress, the implants may become visible under the skin. Autologous dermafats grafts have also been attempted.³⁸ In general, the surgical options are generally much more costly than injectable options.

Conclusion

Temporary injectable fillers are useful in HIV facial lipoatrophy but must be injected into the subdermal tissue in a volume sufficient to achieve optimal correction. Often the cost associated with larger volumes and repeat treatments is prohibitive.

Many patients with HIV lipoatrophy demand more permanent injectable fillers. Although newer, more permanent synthetic fillers are being developed and investigated outside the United States, liquid silicone remains the only permanent injectable filler that is legally available within the United States, with early studies suggesting safety, efficacy,

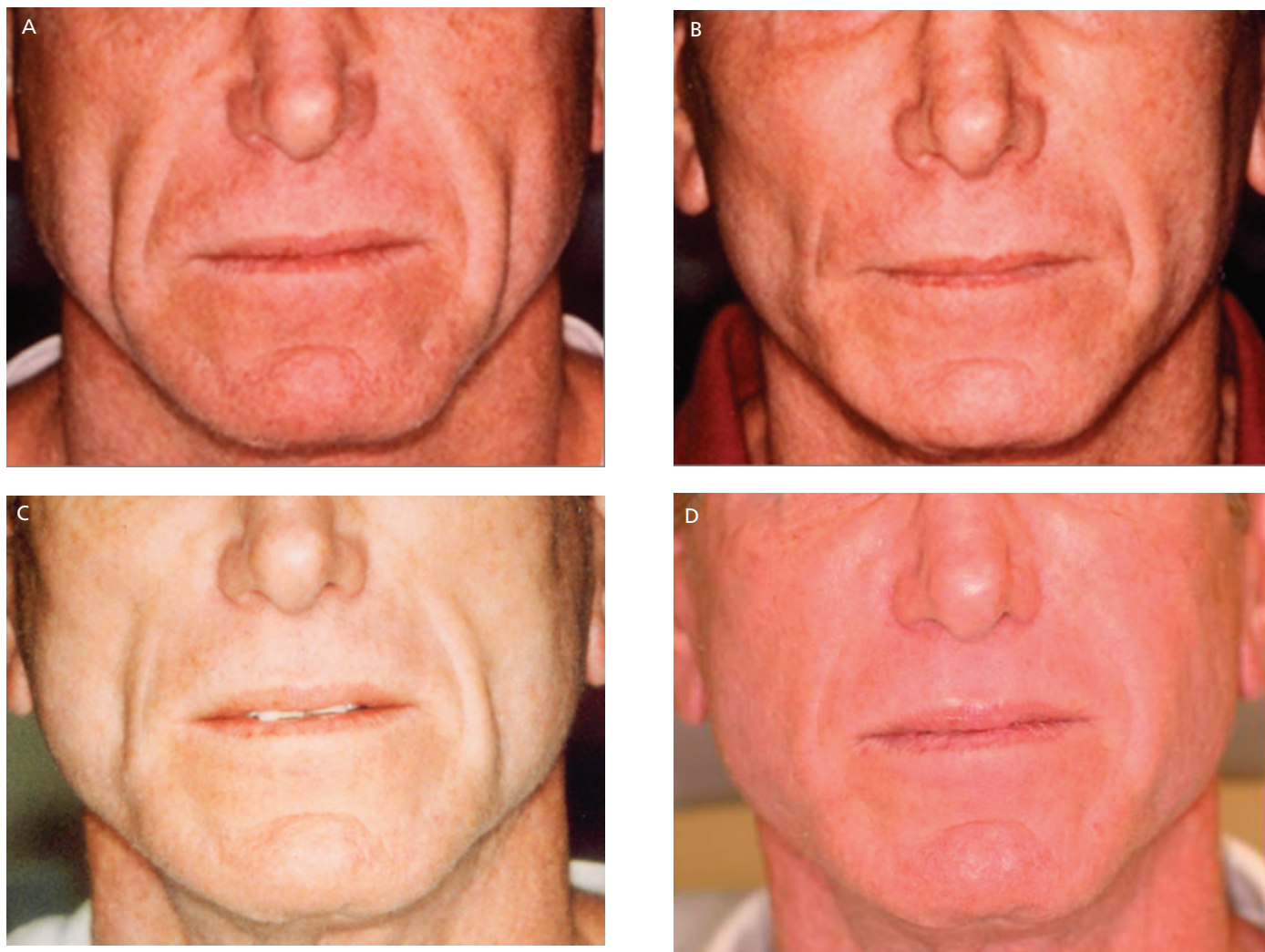


Figure 9. (A) Before face-lift. (B) One month after face-lift. (C) Two years after face-lift. Note that depressions have returned. (D) After 7.5 cc of silicone over five monthly treatments (the photograph was taken 9 months after the last silicone injection).

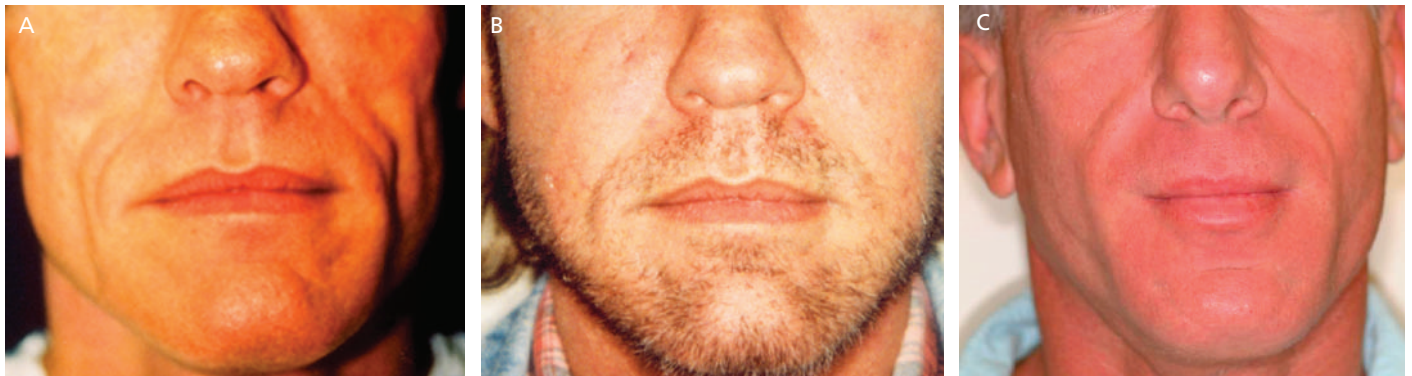

Figure 10. (A) Before Alloderm implants. (B) Two weeks following Alloderm implants (implanted through a periauricular face-lift incision). (C) Two years after Alloderm implants. Note that the grafts have become reabsorbed.

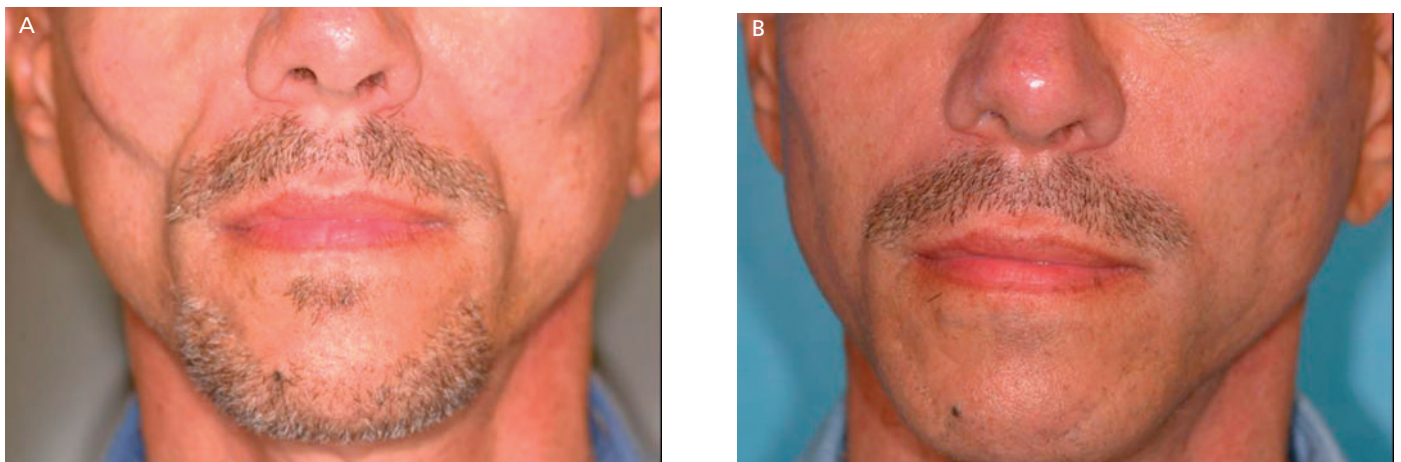


Figure 11. (A) After rigid silicone implants implanted in the malar area to combat lipoatrophy. The lipoatrophy has progressed, revealing the sharp, hard edge of the implants. (B) After 10.8 cc microdroplet silicone over five monthly treatments (the photograph was taken 3 months after the last silicone treatment).

and high patient satisfaction for HIV facial lipoatrophy. However, longer-term safety in HIV remains to be proven.

References

- Centers for Disease Control and Prevention. Basic statistics. Available at: <http://www.cdc.gov/hiv/stats.htm#international> (accessed August 26, 2005)
- Lichtenstein KA, Ward DJ, Moorman AC, et al. Clinical assessment of HIV-associated lipodystrophy in an ambulatory population. *AIDS* 2001;15:1389-98.
- Bastard JP, Caron M, Vidal H, et al. Association between altered expression of adipogenic factor SREBP1 in lipoatrophic adipose tissue from HIV-1 infected patients and abnormal adipocyte differentiation and insulin resistance. *Lancet* 2002;359:1026-31.
- Brinkman K, Smeitank JA, Romijn JA, Reiss P. Mitochondrial toxicity induced by nucleoside-analog reverse-transcriptase inhibitors is a key factor in the pathogenesis of antiretroviral-therapy-related lipodystrophy. *Lancet* 1999;354:1112-5.
- Carr A, Workman C, Smith DE, et al. Abacavir substitution for nucleoside analogs in patients with HIV lipoatrophy: a randomized trial. *JAMA* 2002;288:207-15.
- Collins E, Wagner C, Walmsley S. Psychosocial impact of the lipodystrophy syndrome in HIV infection. *AIDS Reader* 2000;10:546-51.
- Arioglu E, Duncan-Morin J, Sebring N, et al. Efficacy and safety of troglitazone in the treatment of lipodystrophy syndromes. *Ann Intern Med* 2000;133:263-74.
- Sutinen J, Hakkinen AM, Westerbacka J, et al. Rosiglitazone in the treatment of HAART associated lipodystrophy (HAL): a randomized, double-blind, placebo-controlled study. Program and abstracts of the 9th Conference on Retroviruses and Opportunistic Infections, Feb 24-28, 2002, Seattle, WA.
- Gelato MC, Mynaric DC, Quick JL, et al. Improved insulin sensitivity and body fat distribution in HIV-infected patients treated with rosiglitazone: a pilot study. *J Acquir Immune Defic Syndr* 2002;31:163-70.
- O'Mahony C, Price LM, Nelson M. Lipodystrophy despite anabolic steroids. *Int J STDs AIDS* 1998;9:619.
- Engleson ES, Glesby MJ, Mendez D, et al. Effect of recombinant human growth hormone in the treatment of visceral fat accumulation in HIV infection. *J Acquir Immune Defic Syndr* 2002;30:379-91.
- Jones D. Treatment of HIV facial lipoatrophy. Presented at the ASDS (American Society of Dermatologic Surgery)-ACMMSCO (American College of Mohs Micrographic Surgery and Cutaneous Oncology) Combined Annual Meeting; 2002 Oct 31-Nov 3; Chicago, IL.
- James J, Carruthers A, Carruthers J. HIV-associated facial lipoatrophy. *Dermatol Surg* 2002;28:979-86.
- Tsao S. Injectable Alloderm for augmentation of HIV-positive protease inhibitor-induced facial lipoatrophy. Presented at the ASDS-

- ACMMSCO Combined Annual Meeting; 2002 Oct 31–Nov 3; Chicago, IL.
15. Burres S. Preserved particulate fascia lata for injection: a new alternative. *Dermatol Surg* 1999;25:790–4.
 16. Jones D. HIV facial lipoatrophy: etiology and methods of correction. In: Klein AW, editor. *Tissue augmentation in clinical practice: procedures and techniques*. New York: Marcel Dekker; 2006..
 17. Caye N, Le Fourn B, Pannier M. Surgical treatment of facial lipoatrophy. *Ann Chir Plast Esthet* 2003;48:2–12.
 18. Sherman R. Autologous fat transfer for HIV lipodystrophy. *Cosmet Dermatol* 2003;16:34–45.
 19. Serra-Renom JM, Fontdevila J. Treatment of facial fat atrophy related to treatment with protease inhibitors by autologous fat injection in patients with human immunodeficiency virus infection. *Plast Reconstr Surg* 2004;114:551–5.
 20. Moyle GJ, Lysakova L, Brown S, et al. A randomized open label study of immediate vs. delayed poly(lactic acid) injections for the cosmetic management of facial lipoatrophy in persons with HIV infection. *HIV Med* 2004;5:82–97.
 21. Amard P, St Marc T, Katz P. The effects of poly(lactic acid) (NewFill) as therapy for lipoatrophy of the face [abstract]. Presented at the Second International Workshop on Adverse Drug Reactions and Lipodystrophy in HIV; 2000 Sep 13–15; Toronto, Canada.
 22. LaFaurie M, Dolivo M, Boulu D, et al. Treatment of facial lipoatrophy with injections of poly(lactic acid) in HIV-infected patients. Presented at the 10th Conference on Retroviruses and Opportunistic Infections; 2003 Feb 10–14; Boston, MA.
 23. Valantin MA, Aubron-Olivier C, Ghosn J, et al. Poly(lactic acid) implants (NewFill®) to correct facial lipoatrophy in HIV-infected patients: results of the open-label study VEGA. *AIDS* 2003;17:2471–7.
 24. Narins R, Brandt F, Leyden J, et al. A randomized, double-blind, multicenter comparison of the efficacy and tolerability of Restylane versus Zyplast for the correction of nasolabial folds. *Dermatol Surg* 2003;29:588–95.
 25. Walther RA. Facial lipodystrophy in patients with HIV is troublesome to treat. *Lakartidningen* 2002;99:3826–9.
 26. Jones DH, Carruthers A, Orentreich D, et al. Highly purified 1000 centistoke oil for treatment of HIV-associated facial lipoatrophy. *Dermatol Surg* 2004;30:1276–86.
 27. Glogau R. HIV associated lipodystrophy and e-PTFE implants. Presented at the Annual Meeting of the American Society of Dermatologic Surgery; 2000 Nov 2–5; Denver, CO.
 28. Brody H. Complications of expanded polytetrafluoroethylene (e-PTFE) facial implant. *Dermatol Surg* 2001;27:792–4.
 29. Serra M. Facial implants with polymethylmethacrylate (PMMA) for lipodystrophy correction: 36 months follow up. Presented at the 14th International AIDS Conference; 2002 July 7–12; Barcelona, Spain.
 30. Del Pino V. Surgical therapy with polyacrylamide gel of facial lipoatrophy. Presented at the 3rd European Workshop on Lipodystrophy and Metabolic Disorders; 2002 Apr 25–27; Marbella, Spain.
 31. de Bree R, Middelweerd R, Van der Wall I. Severe granulomatous inflammatory response induced by injection of polyacrylamide gel into the facial tissue. *Arch Facial Plast Surg* 2004;6:204–6.
 32. Huo M, Huang J, Qi K. Toxicities of polyacrylamide gel implants. *Zhonghua Zheng Xing Wai Ke Za Zhi* 2002;18:79–80.
 33. Pacini S, Ruggiero M, Morucci G, et al. Bio-Alcamid, a novel prosthetic polymer, does not interfere with morphological and functional characteristics of human skin fibroblasts. *Plast Reconstr Surg* 2003;111:489–91.
 34. Pacini S, Ruggiero M, Morucci G, et al. Bio-Alcamid: a novelty for reconstructive and cosmetic surgery. *Ital J Anat Embryol* 2002;107:209–14.
 35. Protopapa C, Giuseppe S, Caporale D, Cammarota N. Bio-Alcamid™ in drug-induced lipodystrophy. *J Cosmet Laser Ther* 2003;5:226–30.
 36. Sklar J, White S. Radiance FN. A new soft tissue filler. *Dermatol Surg* 2004;30:764–8.
 37. Binder W, Bloom DC. The use of custom-designed midfacial and submalar implants in the treatment of facial wasting syndrome. *Arch Facial Plastic Surg* 2004;6:394–7.
 38. Berish S, Baum T, Robbins N. Treatment of human immunodeficiency virus-associated lipodystrophy with dermofat graft transfer to the malar area. *Plast Reconstr Surg* 2004;113:363–70.

Commentary

The author has written a comprehensive report on the state of the treatments for human immunodeficiency virus (HIV) lipoatrophy at this time. Weeding through the mire of soft tissue fillers that are used and exploited within the HIV community is not an easy task. This article beautifully compares the existing fillers scientifically. Although the ideal filler may not exist at this time, there is significant hope in existing treatments to allay the psychosocial stigmata of the HIV community by selecting appropriate fillers to correct defects either for the entire face or for the most significant areas. The trend to layer or to combine different fillers

in different areas has begun in the cosmetic treatment of non-HIV-associated defects. This trend may carry through into the treatment of HIV-associated depressions as well. Although some fillers may be expensive or difficult to use, dermatologic surgeons are best qualified to be aware of the options and potential combinations available for relief of suffering in this patient population. Most important, patients need to realize the longevity and the complications inherent within their choices. This article is a superb reference point for those decisions.

HAROLD J. BRODY, MD
Atlanta, GA